

ORIGINAL PAPER

POSITIONAL VARIATIONS OF THE EXTERNAL
AND THE INTERNAL CAROTID ARTERY

Jasmin DELIĆ¹
Alma BAJTAREVIĆ²
Eldar ISAKOVIĆ¹

¹Department of Anatomy, School of
Medicine, University of Tuzla,
Tuzla

²PZU „Medicom“,
Zenica

Bosnia and Herzegovina

Received: 31.03.2009
Accepted: 16.09.2009

Correspondence to:
Jasmin Delić
School of Medicine, University of Tuzla
Univerzitetska 1, 75000 Tuzla
Bosnia and Herzegovina

tel: +387 35 260 320
e-mail: jasmin.delic@untz.ba

ABSTRACT

Introduction: clinical examination and surgical procedures require the knowledge of anatomical peculiarities of a complex area such as neck, especially if the anomalies in development of vascular system may occur.

Aim: to investigate the mutual relation of the initial parts of the internal carotid artery and the external carotid artery, as well as the height of crossing of these blood vessels.

Patients and methods: we evaluated 50 patients referred to diagnostic center of the PZU „Medicom“ Zenica, by using of magnetic resonance imaging (MRI) of the neck.

Results: External carotid artery is placed medially and goes to the frontal side of the internal carotid artery in 90% cases. In 7% of cases the right internal carotid artery is placed laterally from the internal carotid artery. Divergent position, where the internal carotid artery (medially) and the external carotid artery go away from each other, was found in 1% of cases. We also found that the internal carotid artery and external carotid artery cross approximately 3.04 cm above the bifurcation (at right 3.05 cm and at left 3.12 cm) and the height of the crossing varies from 1.3 cm to 4.2 cm (at right 1.3 cm to 4.2 cm, and at left 1.5 cm to 4.1 cm). The height of crossing is symmetric in 18% of cases. Reversal of the position of the external and internal carotid arteries was found in 7% cases.

Conclusion: The possibility of an inversed disposition of the internal and external carotid arteries must be held in mind when performing arterial ligatures in the carotid triangle, to avoid damage to the internal carotid artery or haemorrhagic accidents.

Keywords: external carotid artery, internal carotid artery, anatomy, variations

INTRODUCTION

Knowledge on the anatomical variations of the blood vessels is necessary for the correct interpretation of results obtained by means of different radiographical techniques, mainly because of the significant rates of the occurrence of variations and anomalies. Patients having anatomical anomalies and variations are more exposed to artery aging and earlier appearance of cerebrovascular diseases.¹ Insufficiency of cerebral vascularisation is caused by morphologic anomalies in

the external and internal carotid artery in 10-15% of cases. Safe and efficient hemostasis in the cases with abundant bleeding of maxillofacial and nasopharyngeal region also requires detailed knowledge of the local anatomy.^{2,3}

In the classic anatomy textbooks, it is described that initial part of the external carotid artery is placed medially and in the front of the internal carotid artery, but in the height of the angulus mandibulae (mandible angle) it crosses the internal carotid artery and reaches its outer side. Variations of mutual positions of these

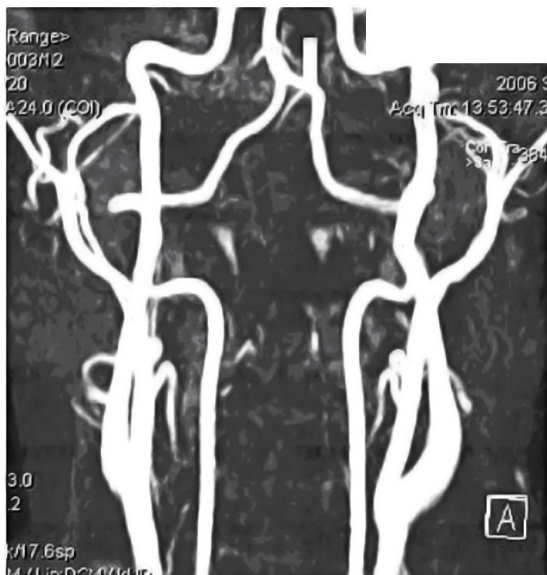

Figure 1. External carotid artery is placed medially from the internal carotid artery and crosses it in frontal side.

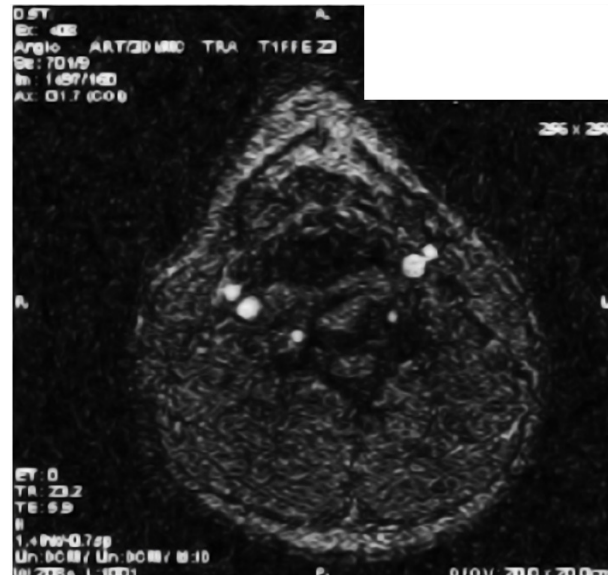


Figure 3. Both-sided, symmetric, lateral position of the external carotid artery in relation to the internal carotid artery

blood vessels also exist, when external carotid artery can be placed either laterally and backward, or laterally and frontally in relation to the internal carotid artery.^{4,5,6,7}

The objective of this research was to investigate mutual relation of the initial parts of the internal carotid artery and external carotid artery, as well as the height of crossing of these blood vessels.

PATIENTS AND METHODS

Prospective research involved 50 consecutive adult patients of both sexes, referred to diagnostic center of the PZU „Medicom“ Zenica for various reasons. All patients were evaluated by using magnetic resonance imaging (MRI) angiography (non-invasive method without adding contrast) of the neck.

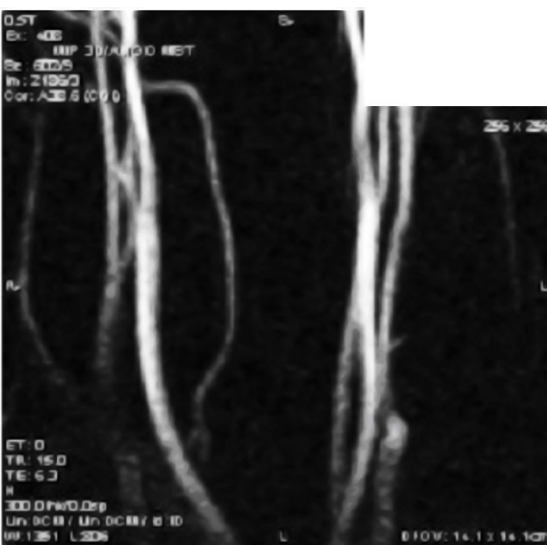


Figure 2. External carotid artery is placed laterally from the internal carotid artery (unilaterally)

RESULTS

Variations of mutual relation of the external carotid artery and internal carotid artery were expressed in four types:

Type 1. External carotid artery in its initial part is placed medially and goes to the front side of the internal carotid artery in 90% of total number of examinees (Figure 1).

Type 2. In 7% of the total number of the examinees, the right external carotid artery is placed laterally from the internal carotid artery. Symmetric (bilateral) lateral position of the external carotid artery in relation to the internal carotid artery was found in 2% of cases (Figures 2, 3).

Type 3. Divergent position, where the internal carotid artery (medially) and external carotid artery (laterally) go away from each other, without crossing, was found in 1% of the total number the examinees (Figure 4).

Type 4. In 1% of total number of the examinees the right external carotid artery and the right internal carotid artery cross two times. Above the bifurcation the external carotid artery is placed laterally, then from the front side it goes across internal carotid artery and is placed medially from it. Proximally from this crossing (1.5 cm) the external carotid artery goes again across the internal carotid artery and is placed laterally from it. (Figure 5).

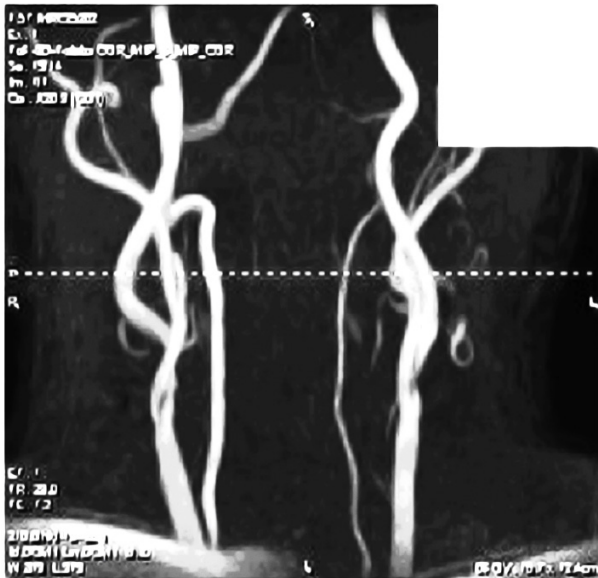

Figure 5. Double cross of the internal carotid artery and external carotid artery

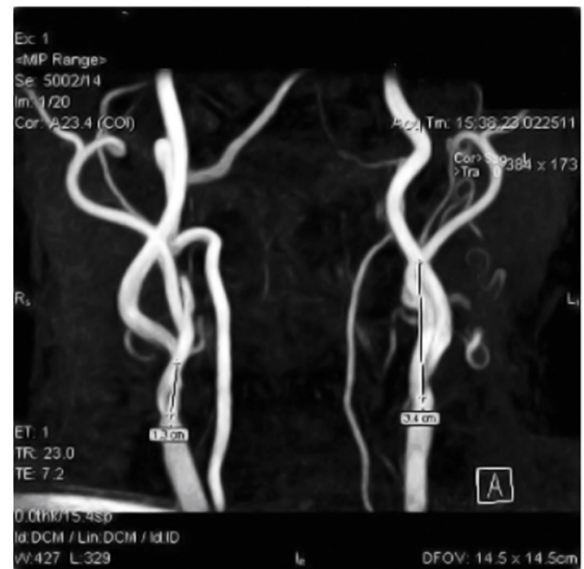

Figure 6. Crossing of the internal carotid artery and external carotid artery (height of crossing 1.3 cm)

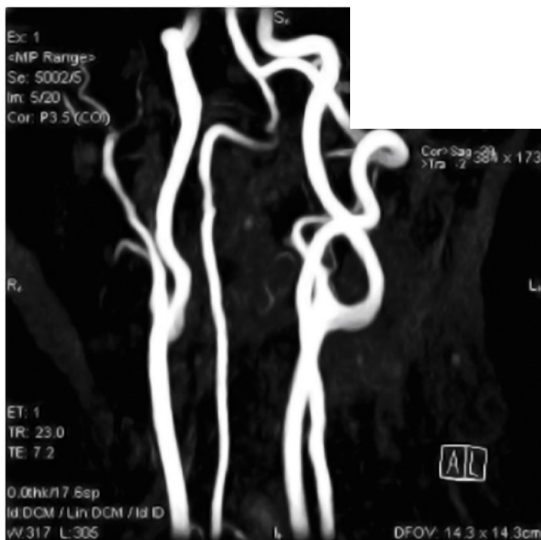

Figure 4. Divergent position of the right internal carotid artery (medially) and the right external carotid artery

crossing was 2.1 cm (Figure 6).

DISCUSSION

The external carotid artery is placed medially and extends to the front side of the internal carotid artery in 90% of cases. In 7% of cases the right external carotid artery is placed laterally from the left internal carotid artery. This positional variation is described in 4.3 – 15% of examinees in papers published by Prendes et al,⁴ Ueda et al,⁵ Bussak et al,⁶ Trigaus et al,⁷ James⁸ and Ito et al.⁹ Symmetric (bilateral) lateral position of external carotid artery in relation to internal carotid artery was found in 2% of cases. Divergent position, where internal carotid artery (medially) and external carotid artery (laterally) go away from each other was also found in 1% of cases.

Variations of the height of the internal carotid artery and external carotid artery were also found. Internal carotid artery and external carotid artery cross approximately at 3.03 cm above the bifurcation (Table 1).

Height of crossing of these arteries is symmetric in 18% of total number of the examinees, and in 76% it is of different values. Average height of crossing of the internal carotid artery and external carotid artery in relation to the bifurcation, amounts at right 3.04 cm, at left 2.99 cm, and the largest difference in their height of

Right internal carotid artery and right external carotid artery cross two times in 1% of cases. Above the bifurcation, external carotid artery is placed laterally, then from front side it goes across the internal carotid artery and is placed medially from it. Proximally from this crossing (1.5 cm) the external carotid artery goes across the internal carotid artery and is placed laterally from it. Our results indicate that internal carotid artery and external carotid artery cross approximately 3.04 cm above the bifurcation (right 3.05 cm and left 3.12 cm), and the height of the crossing varies from

Table 1. Height of crossing of the internal carotid artery and external carotid artery

	M	Min	Max	SD	SE	KV
L	3.07	1.50	4.20	0.56	0.08	0.31
R	3.00	1.30	4.10	0.46	0.06	0.22

1.3 to 4.2 cm (right 1.3 cm to 4.2 cm, and left 1.5 cm to 4.1 cm). Height of the crossing is symmetric in 18% of cases. Height of crossing of skeletopically symmetric bifurcations of the a. carotis communis is 3.20 cm, and of asymmetric bifurcations it is 2.89 cm. Available data on the height of crossing of the internal carotid artery and the external carotid artery were not found in the recent medical literature.

CONCLUSION

Concerning the participation of inversion and positional variations of internal carotid artery and external carotid artery (9%), a caution must be paid with ligation of blood vessels of the carotid triangle, because if these blood vessels are not distinguished, this may have catastrophic consequences in cerebral circulation or it can cause bleeding in the region of the external carotid artery.

REFERENCES

1. Benson M, Hamer JT. Anomalous origin of the occipital artery from internal carotid artery. *Vasc Surg* 1998; 8(5): 653-8.
2. Haccein-Bey L, Daniels DL, Ulmer JL et al. The ascending pharyngeal artery: branches, anastomoses, and clinical significance. *AJNR Am Neuroradiol* 2002; 23(7): 1246-56.
3. Shang JB, Li YH, Chen Y et al. Clinical application of transarterial embolization for massive hemorrhage in the nasopharyngeal and maxillofacial regions. *Di Yi Jun Yi Da Xue Xue Bao* 2004; 24(2):210-2. PMID:14965831
4. Prendes JL, McKinney WM, Buonanno FS, Jones AM. Anatomic variations of the carotid bifurcation affecting doppler scan interpretation. *J Clin Ultrasound* 1980; 8(2): 147-50. doi:10.1002/jcu.1870080211 PMID:6767749
5. Ueda, S, Konyama Y, Takase K. Peripheral hypoglossal nerve palsy caused by lateral position of the external carotid artery and an abnormally high position of bifurcation of the external and internal carotid arteries – case report. *Stroke* 1984; 15(4):736-9. PMID:6464069
6. Bussaka H, Sato N, Oguni T et al. Lateral position of the external carotid artery. *Rinsho Hoshasen* 1990; 35(9): 1061-3. PMID:2232281
7. Trigaux JP, Delchambre F, Van Beers B. Anatomical variations of the carotid bifurcation: implications for digital subtraction angiography and ultrasonography. *Br J Radiol* 1990; 63(747): 181-5. doi:10.1259/0007-1285-63-747-181 PMID:2185866
8. James P. Anatomy and anatomical variations of the major arteries in the neck. *Asum Bulletin* 2001; 4(3): 18-9.
9. Ito H, Mataga I, Kageyama I, Kobayashi K. Clinical anatomy in the neck region – the position of external and internal carotid arteries may be reversed. *Okajimas Folia Anat Jpn* 2006; 82(4): 157-67. doi:10.2535/ofaj.82.157 PMID:16526574