

## CASE REPORT

METASTATIC RENAL CELL ADENOCARCINOMA OF THE  
GALLBLADDER: A CASE REPORT

Siniša MAKSIMOVIĆ

*General Hospital "Sveti Vracevi"  
Bijeljina, Bosnia and Herzegovina**Received: 01.02.2009**Accepted: 15.02.2009***Correspondence to:***Sinisa Maksimovic, MD, PhD  
General hospital "Sveti Vracevi"  
Bijeljina, Bosnia and Herzegovina**email: makss@telrad.net*

## ABSTRACT

**Background:** Gallbladder (GB) involvement in patients with renal cell carcinoma (RCC) is extremely rare.**Case report:** We present a report of a 58-year-old man with a metachronous metastatic contralateral renal cell adenocarcinoma of the gallbladder. The patient presented with the acute right upper quadrant pain and cholecystitis three years after resection of the primary renal neoplasm. Gallbladder tumor was detected clinically. The tumor was located in the fundus of the gallbladder under the lamina propria mucosa with subserosal invasion. Blood biochemistry results were in normal ranges as well as carcinoembryonic antigen (CEA) and carbohydrate antigen 19-9 (Ca 19-9). A histopathological examination revealed that the mucosal surface was covered with yellowish fibronectin tissue but contained no tumor cell. The tumor was located under the lamina propria mucosa with subserosal invasion. Tumor cells were positive for PAS, vimentin and CD 10, but negative for carcinoembryonic antigen (CEA), carbohydrate antigen (Ca 19-9) and cytokeratin 7 (CK7). Additional specific and immunohistochemical tests confirmed that gallbladder tumor was a metastasis of renal cell carcinoma. Renal cell adenocarcinoma was specified as Fuhrman's grade 2.**Conclusions:** Pre-operative imaging studies are often futile for the differentiation between primary and secondary tumors of the gallbladder. Primary tumors of the gallbladder often coexist with gallstones while polypoid lesions in an acalculous gallbladder are frequently associated with metastasis.**Keywords:** renal cell carcinoma, gallbladder metastases, surgery

## INTRODUCTION

Renal cell carcinoma (RCC) is a relatively rare tumor, accounting for approximately 3% of all adult malignancy. RCC has a high metastatic potential and 25% to 57% of patients exhibit overt evidence of metastatic disease at the time initial presentation accounts for approximately 85-90% of all renal tumors.<sup>1</sup> Although RCC is known to metastasize primary to the lung, lymph node, bone, liver, brain and ipsilateral or contralateral adrenal gland, unusual metastatic site such as the epidermis, urinary bladder and corpus cavernosus have been cited in several published reports and studies.<sup>2</sup> The gallbladder is a rare site of distant metastasis and

when found, most of the time the primary tumor was malignant melanoma. Metastases can be synchronous or can occur metachronously decades after the primary diagnosis. A review of the literature revealed only a small number of reports of gallbladder metastasis of RCC, of which two were discovered at autopsy.<sup>3</sup> We report a case of metachronous gallbladder metastasis following the initial contralateral nephrectomy due to renal cell carcinoma.

## CASE REPORT

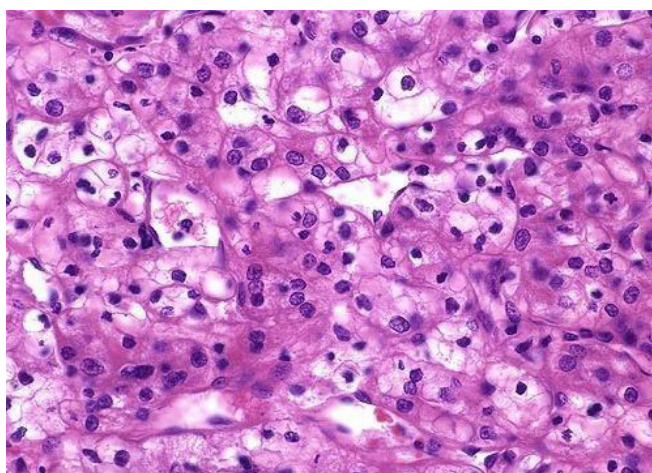
We present a report of a 58-year-old man with a metachronous RCC metastasis to the gallbladder.

A.P. is a 58-year-old male who noted the onset of painless gross hematuria in June 2006. His past medical history was unremarkable except for essential hypertension controlled with medications and a history of peptic ulcer disease. An intravenous pyelogram revealed poor visualization of the left kidney and an abdominal-pelvic CT scan demonstrated distortion of the right renal pelvis secondary to a tumor mass. Except for this finding and a small renal cysts bilaterally, the CT scan was unremarkable.

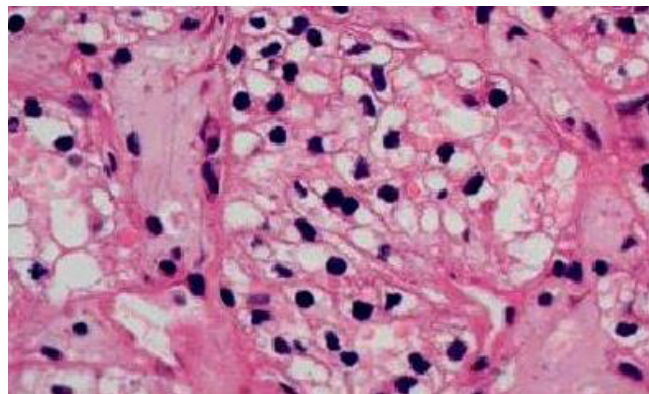
Within the two weeks of presentation, a left radical nephrectomy was performed. The entire kidney was removed without disruption. The specimen revealed an intact 8x7x5 cm tumor located in the midportion of the kidney. The tumor was near but did not invade the renal pelvis. No invasion of the renal vein was noted. Microscopically, the tumor was a clear cell type of renal adenocarcinoma without involvement of the renal capsule. Vascular and urethral margins were free of tumor. Renal cell adenocarcinoma was classified as Fuhrman's grade 2 (*Figure 1*).

A scheduled follow up abdominal-pelvic CT scan was performed one year later. There was no evidence of recurrent tumor. Over the next three years, during which the patient reported no symptoms, follow-up office visits with the patient's urologist revealed normal physical examinations.

The patient presented with the acute right upper quadrant pain and cholecystitis three years after resection of the primary renal neoplasm. Abdominal ultrasonography showed a hyperechoic mass with a mosaic pattern, measuring 3, 5 x 3.0 cm in diameter, filling the gallbladder. Abdominal computed tomography (CT) clearly demonstrated a pedunculated tumor in the gallbladder without infiltration outside the gallbladder wall and regional lymphadenopathy.



**Figure 1:** Hematoxylin-eosin stain (10x) of the resected kidney mass. Left half of the field illustrates conventional clear cell type renal cell carcinoma demonstrated by organoid growth pattern and acini lined by clear cells



**Figure 2.** Higher magnification showing the gall bladder with tumor cells with clear, abundant cytoplasm consistent with metastatic renal cell carcinoma (x400)

The patient underwent laparotomy and simple cholecystectomy in November 2008, 2,5 years after resection of the primary renal neoplasm. The tumor was palpable and movable within the fundus of the gallbladder, without gross involvement of the exterior surface of the gallbladder, liver or regional lymph nodes. Gallstones were not found in the bile. Histological findings revealed that the mucosal surface was covered with yellowish-white fibrous necrotic tissue but contained no tumor cells. The tumor was located under the lamina propria mucosa with subserosal invasion. Tumor cells proliferated through abundant vascular structures and revealed alveolar, tubular and, in part, papillary growth (*Figure 2*).

All tumor cells were polygonal with clear cytoplasm and eccentric hyperchromatic nuclei. The cells were positive for PAS, vimentin, and CD10, but negative for carcinoembryonic antigen (CEA), carbohydrate antigen (CA19-9), Leu-M1, epithelial membrane antigen (EMA), and cytokeratin 7 (CK7).

## DISCUSSION

RCC is known for its varied presentation and its propensity to metastasize by way of both venous and lymphatic routes. M. J. Kim and K. W. Kim<sup>4</sup> found that 23% of patients with RCC present initially with metastatic disease and 25% develop metastatic disease within the 5 years of nephrectomy. RCC can, however, metastasize to virtually any organ, including the thyroid, pancreas, skeletal muscle, and skin or underlying soft tissue. Gallbladder involvement is rare and may be an incidental finding or a symptomatic condition that prompts further investigation. Acute cholecystitis and right upper quadrant pain have been reported with gallbladder involvement.<sup>4,5</sup>

On autopsy specimens, gallbladder involvement is rare. The incidence of gallbladder metastasis has been reported to be 0.57% (3 of 523 cases of RCC).<sup>6</sup> In

a large autopsy series, Tian<sup>7</sup> reported 4 cases of gallbladder disease at autopsy in a separate series with 687 cases.

Metastatic disease is even rarer in the period later in the life. In a prior analysis of 20 cases of renal cell carcinoma metastatic to the gallbladder, no significant difference was observed between right and left kidneys or between males and females.<sup>6</sup> Of these 20 cases, 8 occurred more than 3 years after initial nephrectomy. Ishizawa<sup>8</sup> reported that secondary carcinomas hematogenously metastasizing from primary organs to the gallbladder initially generate flat nodules below the mucosa and later grow into pendunculated tumors.

Primary clear cell carcinoma of the gallbladder has also been reported.<sup>9</sup> In some cases, especially in the setting of possible metachronous lesion, it may be difficult to distinguish between primary clear cell carcinoma of the gallbladder and the RCC metastatic disease to the gallbladder. Special stains, such as CA-IX, vimentin, chromogranin A, synaptophysin, PAS, CD10, CEA, and CA19-9, can be used to assist in these cases.<sup>1,9,10</sup> It was very difficult for our pathologist to differentiate between the primary clear cell carcinoma or clear cell carcinoid tumor and metastatic renal cell carcinoma due to histological similarities. The gallbladder clear cell carcinoid tumor shows reactivity for chromogranin A and synaptophysin immunohistochemical stains. But this type of tissue staining was not available to us.

Most patients with localized renal tumors are cured by surgical resection. In the setting of metastatic disease, patients should be clinically evaluated for metastasectomy and systemic therapy. Immunotherapy with interferon or interleukin is the most established systemic treatment, but recent advances include the use of targeted (tyrosine kinase) therapy. Our patient received interleukin-2 and had a stable tumor burden 20 months after treatment. Considering his prognosis, multiple organ metastatic disease correlates with a worse outcome.<sup>11</sup> However, Park et al.<sup>12</sup> recently reported a case similar to ours, with a simultaneous nephrectomy and cholecystectomy due to a concurrent RCC and gallbladder metastasis and with a 30-month disease-free survival, without systemic therapy.

## CONCLUSION

In conclusion, RCC metastasis to the gallbladder is indeed unusual. The majority of such patients are asymptomatic. Management should be undertaken in the context of the patient's condition and with considerations for systemic therapy. Preoperative imaging studies are not of a particular use for differentiation between primary and secondary tumors of the gallbladder. Primary tumors of the gallbladder often coexist with gallstones while a polypoid lesion in a gallbladder without calculi is more suggestive for metastasis.

## REFERENCES

1. Hellenthal NJ, Stewart GS, Cambio A et al. Renal cell carcinoma metastatic to gallbladder a survival advantage to simultaneous nephrectomy and cholecystectomy. *Int Urol Nephrol*. 2007; 39: 377-9.
2. Park JS, Chae YS, Hong SJ et al. Metastatic renal cell carcinoma of the gallbladder. *Yonsei Medical Journal*. 2003; 44(2): 355-8.
3. Nojima H, Cho A, Yamamoto H et al. Renal cell carcinoma with unusual metastasis to the gallbladder. *J Hepatobiliary Pancreat Surg* (2008) 15:209-12.
4. Kim MJ, Kim KW, Kim HC. et al. Unusual Malignant Tumors of the Gallbladder, *Am J Roentgenol*. 2006;187(2):473-80.
5. Thyaviahally YB, Mahantshetty U, Chamarajanagar RS et al. Management of renal cell carcinoma with solitary metastasis. *World Journal of Surgical Oncology* 2005; 48 (3): 1-9.
6. Aoki T, Inoue K, Tsuchida A et al. Gallbladder metastasis of renal cell carcinoma: report of two cases. *Surg Today*. 2002; 32(1):89-92.
7. Tian H, Matsumoto S, Takaki H, et al. Mucin producing carcinoma of the gallbladder: imaging demonstration in four cases. *J Comput Assist Tomogr* 2003; 27:150-4
8. Ishizawa T, Okuda J, Kawanishi T, et al. Metastatic renal cell carcinoma of the gallbladder. *Asian J Surg*. 2006; 29(3):145-8.
9. Cohen HT, McGovern FJ. Renal cell carcinoma. *N Engl J Med*. 2005; 353 (23): 2477-90.
10. Pandey D, Kane SV, Shuklaet PJ al. Isolated gall bladder metastasis from renal cell carcinoma. *Indian J Gastroenterol*. 2006;25(3):161-2.
11. Aoki T, Inoue K, Tsuchida A et al. Gallbladder Metastasis of Renal Cell Carcinoma: Report of Two Cases. *Surg Today* 2002; 32:89-92.
12. Park JS, Chae YS, Hong SJ, Shin DH, Choi JS, Kim BR. Metastatic renal cell carcinoma of the gallbladder. *Yonsei Med J*. 2003; 44(2):355-8.