
CASE REPORT

**THIRD CORONARY ARTERY OBSERVED IN A SOUTH
INDIAN MALE CADAVER: A CASE REPORT**

¹Sreenivasulu REDDY**¹Seetharama BHAT****¹Rakesh VASAVI****²Naveen BANDARUPALLI****³Raghu JETTI****³Venkata RAMANA VOLLALA**

¹*Department of Anatomy, Kasturba
Medical College International Cen-
ter, Manipal*

²*Department of Anatomy, Mamata
Medical College, Khammam*

³*Department of Anatomy, Melaka
Manipal Medical College (Manipal
Campus), International Centre for
Health Sciences, Manipal*

India

Received: 28.01.2010

Accepted: 18.03.2010

Correspondence to:

Venkata Ramana Vollala

Department of Anatomy, Kasturba
Medical College International Center,
Manipal, India

email: ramana_anat@yahoo.co.in

ABSTRACT

We present a case of third coronary artery arising directly from the right aortic sinus of Valsalva in a 60 year old male cadaver. It coursed in the epicardium downward, forward and to left on the sternocostal surface of the right ventricle up to the apex of heart where it anastomosed with left anterior descending artery. During its course it gave small ventricular branches to the right and left ventricles. Clinical importance and embryology of the variation are discussed.

Keywords: coronary artery, aortic sinus, heart, cadaver

INTRODUCTION

The knowledge of coronary artery variations and branching patterns is essential to perform procedures like coronary bypass surgeries, angiography and aortic valve replacement. Some of the variations of coronary arteries include single right or left coronary artery, anomalous origin of right or left coronary artery from pulmonary trunk, origin of left anterior descending artery from right coronary artery, posterior interventricular artery from left anterior descending artery and anomalous origin of right conus artery.¹

Usually right coronary artery gives off right conus artery, which supplies infundibulum of right ventricle. If right conus artery arises directly from right aortic sinus, in such condition it is known as third coronary artery. The anastomoses between the right and left conus arteries form an annulus of Vieussens, which may be an important source for collateral coronary blood flow between the right and left coronary arteries.

CASE PRESENTATION

During regular dissection for first year medical stu-

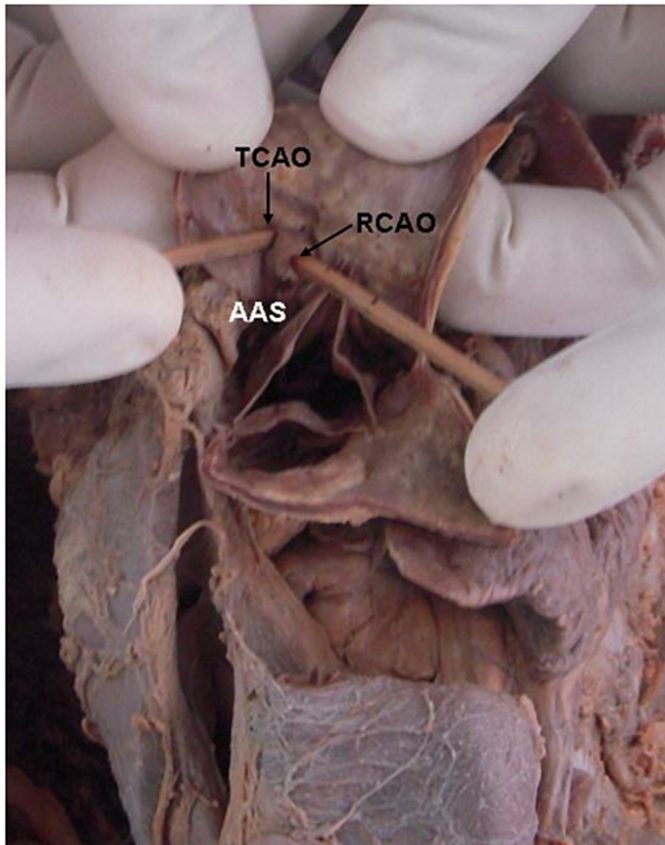


Figure 1. Photograph showing origin of third coronary artery from right aortic sinus.

RCAO – Right coronary artery ostium;
TCAO – Third coronary artery ostium;
AAS – Anterior aortic sinus

dents, we observed third coronary artery arising directly from the right aortic sinus of Valsalva (Figure 1).

Then it coursed in the epicardium downward, forward and to left on the sternocostal surface of the right ventricle up to the apex of heart where it anastomosed with left anterior descending artery (Figure 2). During its course it gave small ventricular branches to the right and left ventricles. There were no other coronary artery variations in the same cadaver.

DISCUSSION

Right conus artery usually arises as a first ventricular branch from right coronary artery. It supplies infundibulum of right ventricle and may anastomose with left conus artery to form an anastomotic necklace known as annulus of Vieussens. Sometimes right conus artery directly arises from the right aortic sinus. In such case it is called third coronary artery. There are some reports about prevalence of third coronary artery in various populations; in Japanese 36.8%,² Iraqis 8%,³ Germans 7.1%,⁴ and in Kenyans 35.1%.⁵ Even though third coronary artery is a common occurrence in other parts of the world, it is seldom reported in Indian subcontinent. According to the previous re-

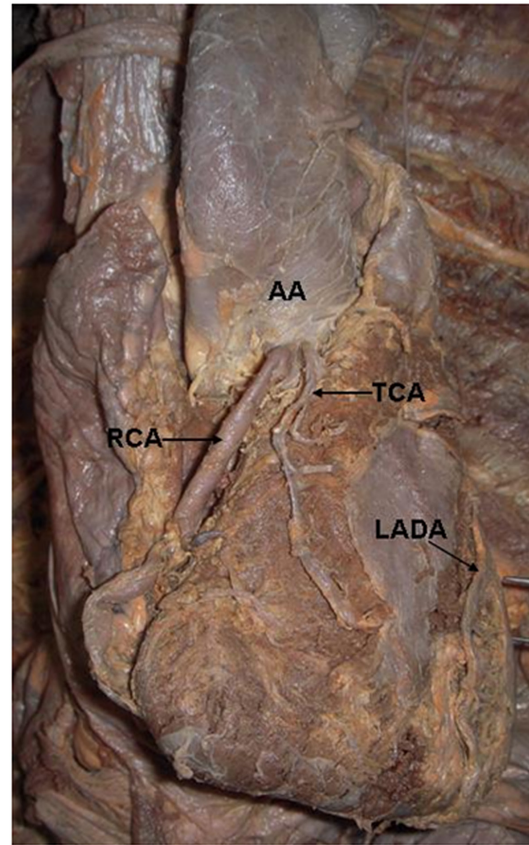


Figure 2. Photograph showing course of third coronary artery and other structures.

TCA – Third coronary artery; RCA – Right coronary artery;
LADA – Left anterior descending artery;
AA – Ascending aorta

ports third coronary artery extends up to the infundibulum of the right ventricle where it most frequently divides into two end branches or reaches the apex of the heart to anastomose with the left anterior descending artery.^{5,6} In some cases third coronary artery is larger than the right coronary artery. Edwards et al. demonstrated that aortic origin of the conus artery is uncommon in neonates and quite frequent in adults.⁷ According to Miyazaki and Kato multiple third coronary artery orifices were observed in adult human hearts and in higher incidence in pathological hearts, however not seen in fetal hearts.^{2,8} These observations suggest that postnatal changes occur in the coronary arterial system and furthermore lack of third coronary artery orifices in fetal hearts suggests that there is a possibility of third coronary artery developing after birth. In the present case third coronary artery was a long and larger branch which extended up to apex of heart and ended after anastomosing with the left anterior descending artery. Third coronary artery, through its branches and anastomoses provide collateral circulation when there is a block in right coronary artery or left anterior descending artery.

CONCLUSION

The awareness of third coronary artery origin, course and distribution is important to clinicians in order to perform cardiac surgical procedures.

REFERENCES

1. Trivellato M, Angelini P, Leachman RD. Variations in coronary artery anatomy: Normal versus abnormal. *Cardiovascular Diseases, Bulletin of the Texas Heart Institute*. 1980;7(4):357-70. PMID:15216239 PMCID:287879
2. Miyazaki M, Kato M. Third coronary artery: its development and function. *Acta Cardiol*. 1988;43(4):449-57. PMID:3262975
3. Kurjia HZ, Cheudhry MS, Olson TR. Coronary artery variation in native Iraqui Population. *Cathet Cardiovasc De-* sign. 1986;12(60):386-90. doi:10.1002/ccd.1810120606 PMID:3815505
4. von Ludinghausen M, Ohmachi N. Right superior septal artery with "normal" right coronary and ectopic "early" aortic origin: a contribution to the vascular supply of the interventricular septum of the human heart. *Clin Anat*. 2001;14 (5):312-19. doi:10.1002/ca.1057 PMID:11754218
5. Olabu BO, Saidi HS, Hassanali J, Ogeng JA. Prevalence and distribution of the third coronary artery in Kenyans, *Int J Morphol*. 2007;25(4):851-4.
6. Lujinovic A, Ovcina F, Tursic A. Third coronary artery. *Bosn J Basic Med Sci*. 2008;8(3):226-9. PMID:18816253
7. Edwards BS, Edwards WD, Edwards JE. Aortic origin of conus coronary artery. Evidence of postnatal coronary development. *Br Heart J*. 1981;45(5):555-8. doi:10.1136/hrt.45.5.555
8. Miyazaki M, Kato M. The developmental study on the third coronary artery of human being. *Gegenbaurs Morphol Jahrb*. 1986;132(2):195-204. PMID:3710116