
CASE REPORT

**THE FIRST EXPERIENCE IN THE TREATMENT OF THE
BASE OF APPENDIX BY HEM-O-LOK CLIPS DURING
LAPAROSCOPIC APPENDECTOMY**

**Ervin MATOVIĆ
Samir DELIBEGOVIĆ***Department of Surgery
University Clinical Center Tuzla**Tuzla, Bosnia and Herzegovina**Received: 11.04.2008**Accepted: 23.09.2008***Correspondence to:***Samir DELIBEGOVIĆ, MD, PhD**Department of Surgery**University Clinical Center Tuzla**Trnovac bb, 75000 Tuzla**Bosnia and Herzegovina**email: delibegovic.samir@gmail.com***ABSTRACT**

During the laparoscopic appendectomy, the base of appendix is usually secured by double endoloop ligatures or by stapler. In this article we will show our initial experience in securing the base of appendix by plastic XL hem-o-lok clip during laparoscopic appendectomy.

Patient, 24 years old with acute appendicitis is admitted to the Department of Surgery. After dissection of mesoappendix and appendicular artery by ultrasonic dissector, two hem-o-lok clips are placed on the base of appendix, and another clip is placed on distal part, which will be removed. Application of clip is made by hem-o-lok XL endoscopic applier.

Keywords: *laparoscopic appendectomy; acute appendicitis; Hem-o-lok clip*

INTRODUCTION

Appendectomy is one of the most frequent operative procedure in abdominal surgery, the number of patients on surgical department is large, what implicate the large cost of treatment. The most important patient issues is the fast recovery and return to the normal activity. There are two methods of treatment of acute appendicitis, laparoscopic and open appendectomy. Laparoscopic appendectomy has the proven advantages in relation to open method.^{1,2} Studies of numerous authors shown that laparoscopic appendectomy is not only favourable to patients due to lesser pain, faster return to everyday activity and better cosmetic effect, it has lesser complications, as well.³ Good results with lesser number of complications caused that today attitude is laparoscopic appendectomy is method of choice for patients with acute appendicitis.⁴

Causes of unsuccessful laparoscopic procedure are different. The most frequent cited causes are unusual

position of appendix, adhesions, bleeding, abscess and the lack of experience of surgeon.⁵ Laparoscopic appendectomy is favourable to obese patients because it avoids the long incision of open procedure with the excellent exposure of intraabdominal organs, what is very difficult to get during open procedure.

Usual technic of securing the base of appendix is by endoloop. The securing the base of appendix by mechanical stapler is very expensive method, that is why it is used very rarely. In this case report we will show the advantages of securing the base of appendix by hem-o-lok clips in relation to standard endoloop procedure, during laparoscopic appendectomy.

CASE REPORT

Patient, 24 years old with acute appendicitis is admitted to the Department of Surgery under suspicion of acute appendicitis. After the short preoperative prep-

aration, it followed entering in operative room and introduction in general endotracheal anesthesia.

Patient was placed in supine position, combined with Trendelenburg position and left lateral position (10° to 15°, inclined toward surgeon). Surgeon and assistant stand on the left side, and monitor is on right patient side. The bladder was decompressed with Foley catheter to avoid their injury during inserting suprapubic ports. Pneumoperitoneum was established with Veress needle through umbilicus and then an endoscope was introduced. Under direct vision, two 5 mm trocars were inserted; one in suprapubic region, a little to the right, and second one in the right lower quadrant, in the level of the first 5 mm port, to acquire triangulation (Figure 1).

After that, the abdominal cavity was inspected. When the decision was brought to perform appendectomy, mesoappendix was mobilized and resected with harmonic scalpel (Ultracision, Ethicon). After dissection of mesoappendix and appendicular artery by ultrasonic dissector, two hem-o-lok clips the size XL (Hem-o-lock, Weck Closure Systems, Research Triangle Park, NC, USA) are placed on the base of appendix, and another clip is placed on distal part, which will be removed (Figure 1).

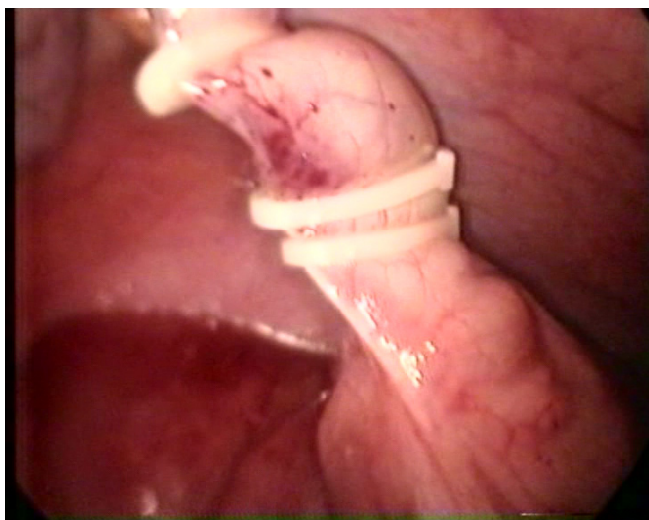


Figure 1. Position of hem-o-lok clips on inflamed appendix

Application of clips is made by applier which is introduced through 10 mm trocar in suprapubic region.

Through supraumbilical 10 mm port was introduced endobag (Ethicon) to remove appendix, avoiding the contamination of the wound.

Cleaning of the right paracolic gutter and Douglass pouch was done using suction/irrigation. If appendix was gangrenous, drain was placed in Douglass pouch.

Urinary catheter is removed the first postoperative day and to patients is given tea and antibiotics and an-

algesics. The patients is discharged from the hospital on the second day, and eighth day skin sutures are removed.

DISCUSSION

Laparoscopic appendectomy, due to its advantages over open procedure, becomes more accepted method in the treatment of acute appendicitis.⁶ In the world, from 80th, laparoscopic appendectomy applies more and more, while in Bosnia and Herzegovina it has no broader clinical implementation. Studies show that patients with laparoscopic appendectomy return to everyday activity 7 days earlier than patients operated by open procedure.⁷ Candidates for laproscopic appendetomy are patients with typical clinical picture of acute appendicitis, and patients with unclear acute findings in the right lower quadrant of abdomen, as well. Laparoscopic approach is also favourable to women because it is easier to examine pelvis, uterus, tubes, ovaries. Relative contraindications for laparoscopic appendectomies are: peritonitis, advanced pregnancy and adhesions in peritoneal cavity, while there are no practically absolute contraindications.

The usage of Hem-o-lok clips, which are polymer material and nonresoptive, for ligation of vessels, ureters, biliary ducts is documented in over 1000 surgical procedures. Cases included 279 resections of rectum and colon, 181 choelcystectomies, and splenectomies, appendectomies and nephrectomies as well.^{8,9,10,11} Design of applier eliminated the drop of clips, and operative time is shorter then endloop application (Figure 2). Application of endloop needs skill and short training, while aspplication of hem-o-lok is very simply and can be done by every surgeon, without previous training.¹² Tactile feeling of hem-o-lok during operation assures the surgeon in safety of closing of clips.

CONCLUSION

Simplicity of application of clips, time of operative procedure and the low cost of clips are advantages of this method of sicuring the base of appendix in relation to standard endloop procedure during laparoscopic appendectomy. With increasing of experience of surgeon this method of securing the base of appendix will become the method of choice.

REFERENCES

1. Golub R, Siddiqui F, Pohl D. Laparoscopic versus open appendectomy: A meta-analysis. *J Am Coll Surg* 1998; 186: 545-53.

2. Heikkinen TJ, Haukipuro P, Hulkko A. Cost-effective appendectomy. Open or laparoscopic? A prospective randomized study. *Surg Endosc* 1998; 12: 1204-8.
3. Kazemier G, De Zeeuw G, Lange JF, Hup WCJ, Bunjer HJ. Laparoscopic vs. open appendectomy, a randomized clinical trial. *Surg. Endosc* 1997; 11: 336-40.
4. Mutson RW, Kelly MD. Simplified technique for laparoscopic appendectomy. *Anz J Surg* 2002; 72: 294-5.
5. Götz F, Pier A, Bacher C. Modified laparoscopic appendectomy in surgery. *Surg Endosc* 1990; 4:6-9.
6. Ali A, Moser MA. Recent experience with laparoscopic appendectomy in a Canadian Teaching Centre. *Can J Surg* 2008; 51: 51-5.
7. Braveti M, Cirocchi R, Giuliani D, Deisol A, Locci E, Spizzirri A, Lamura E, Giustozzi G, Scianameo E. Laparoscopic appendectomy. *Minerva Chir* 2007; 62: 489-96.
8. Schick KS, Hutti TP, Fertmann JM, Hurnung KM, Jauch KW, Hofmann JN. A critical analysis of laparoscopic appendectomy: How experience with 1.400 appendectomies allowed innovative treatment to become standard in a University Hospital. *World J Surg* 2008; 14: 289-93.
9. Bomfim AC, Andreoni C, Miotto A, Araujo M.B, Ortiz V, Poli de Figureido LF, Srougi M. The „Boatmans knot“: A new option for renal hilum ligation during laparoscopic nephrectomy. *Acta Cir Bras* 2005; 20:744-9.
10. Pradeep B, Anant K, Aneesh S, Devendra K, Anil M, Mahendra B. Laparoscopic radical nephrectomy; Our initial experience. *Indian Journal of Urology* 2004; 20: 154-9.
11. Tobias-Machado M, Forseto P, Medina J, Watanabe M, Juliano R, Wroclawski E Laparoscopic radical prostatectomy by extraperitoneal acces with duplication of the open technique. *Int Braz J Urol* 2004; 30: 55-60.
12. Hanssen A, Plotnikov S, Dubois R Laparoscopic appendectomy using a poly-metric clip to close the appendicular stump. *Journal of The Society of Laparo-endoscopic Surgeons* 2007; 11: 59-62.