



CASE REPORT

THE ASSOCIATION OF VENOUS AND CAVERNOUS ANGIOMA—CASE REPORT AND REVIEW OF LITERATURE

Svjetlana MUJAGIĆ¹
Jasmina BEĆIROVIĆ –IBRIŠEVIĆ¹
Haris HUSEINAGIĆ¹
Selma JAKUPOVIĆ²

¹Department of Radiology

²Department of Neurosurgery

University Clinical Center Tuzla,
Tuzla, Bosnia and Herzegovina

Received: 15.07.2010

Accepted: 16.10.2010

Correspondence to:

Svjetlana Mujagić

Ahmeta Kobića 19,

75000 Tuzla, Bosnia and Herzegovina

Phone: +38761661080

Email: svjetlanabh@yahoo.com

ABSTRACT

Isolated cavernous and venous angiomas are common vascular cerebral malformations but their association is less frequent. The presence of venous angioma enhances the risk of bleeding from cavernous angioma. This association is also important for surgical planning. While early extirpation of symptomatic cavernous angioma is recommended, the associated venous angioma has to be preserved due to possible venous infarction.

We report a case of venous angioma associated with cavernous angioma revealed by magnetic resonance imaging after the administration of contrast material, which was not visualised on unenhanced MRI images. The importance of contrast administration in the diagnosis of venous angioma in close vicinity to a cavernoma is emphasised in this report.

Keywords: *venous angioma, cavernous angioma, MRI, contrast*

INTRODUCTION

Vascular malformations of the brain have been classified into four major pathologic types: venous, cavernous, capillary and arteriovenous malformations.¹ Mixed cerebrovascular malformations are defined as any combination of the above.² The most common form of intracranial vascular malformations are venous malformations, also known as venous angiomas (VA) or developmental venous anomalies (DVAs). DVAs are often associated with intracranial cavernous angiomas (CA).³ Most authors report that DVAs are not true vascular malformations and should be considered a variant of normal venous drainage. As a rule, they are quite asymptomatic, and very rarely bleed. On the other hand, CA are true vascular malformations. Associations of CA and DVA are important because of the possibility of bleeding, which is most probably due to the CA.⁴ Surgical resection of the DVA is not recom-

mended due to possible venous infarction.⁵

This report describes a case of VA associated with CA revealed by magnetic resonance imaging (MRI) after the administration of contrast agents, which was not visualised on unenhanced MRI scans. Furthermore, a review of recent literature is provided.

CASE REPORT

A 22-year old male patient with a history of recurrent headaches once-twice a month, over the last 5 years, was admitted to the Department of General Surgery, due to an inguinal hernia. After failed spinal anaesthesia, surgery was performed using general anaesthesia. Three days after surgery the patient developed a severe headache. Unenhanced CT scans revealed a focal, hyperdense lesion, 15x9 mm in size, in the right cerebellar hemisphere with a round, 2 mm hypodense area in the anterior aspect of the lesion, without mass

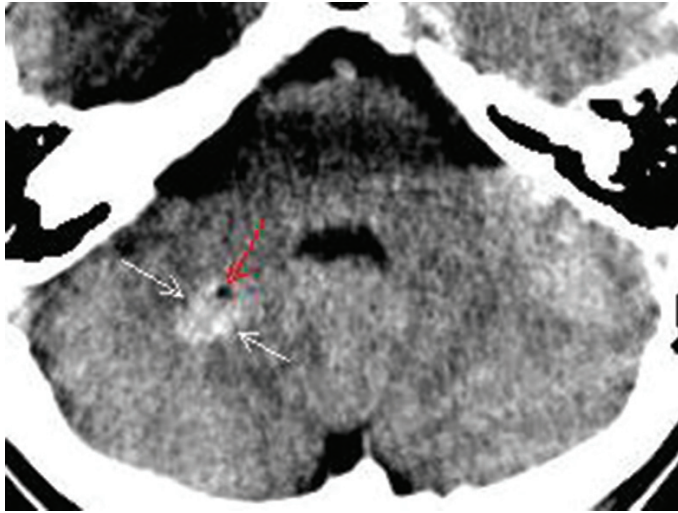


Figure 1. The axial unenhanced CT scan shows a hyperdense lesion in the right cerebellar hemisphere (white arrows) with round, hypodense area in the anterior aspect of lesion (red arrow)

effect or surrounding oedema (Figure 1). Due to this finding, MRI of the brain was performed. Unenhanced MRI scans revealed the lesion with a core of mixed signal intensity on T1 and T2-weighted images, suggesting varying ages of the internal haemorrhages, while the lesion was surrounded by a rim of decreased signal intensity on T2-weighted spin-echo and T2*-weighted gradient-echo images, representing haemosiderin deposits (Figure 2). The popcorn appearance of the core, surrounded by a rim of decreased signal intensity corresponded to CA. On unenhanced MRI images of the brain there was no evidence of other abnormalities (Figure 2, 3).

After contrast administration, contrast enhanced T1-weighted images showed small dilated medullary veins distributed around and within the CA converging on a larger collector vein anterior to CA. This draining vein traversed through the right cerebellar hemisphere, towards the petrosal surface of the cerebellum (Figure 4). This finding corresponded to a VA in close vicinity of the CA. The neurosurgeon was consulted, who suggested further radiological monitoring.

DISCUSSION

VAs or DVAs account for more than 60% of all intracranial vascular lesions.^{3,6} They are encountered in up to 2.5% of autopsy cases, although MR imaging based studies have indicated a much lower incidence, ranging from 0.14 to 0.7%.^{7,8} A DVA is composed of radially arranged medullary veins resembling a “caput medusae” surrounded by normal neural parenchyma and converging into a centrally located dilated trunk.³ The DVA drains toward either the superficial system or,

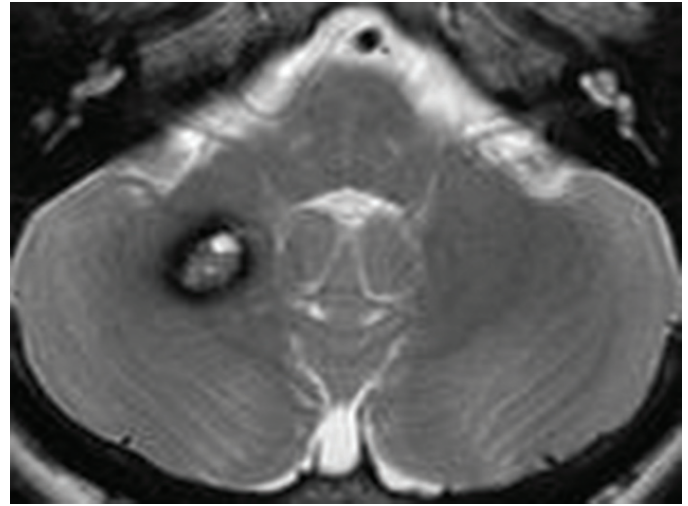


Figure 2. The axial T2-weighted image shows the lesion in the right cerebellar hemisphere which corresponds to the cavernous angioma

rarely, the deep venous system. DVAs are classified as benign lesions because they normally do not present with any clinical symptoms during a person’s lifespan. DVAs appear infrequently to be associated with symptoms and these have usually been due to intracranial haemorrhage or infarction which are often caused by associated CAs rather than the DVAs themselves.^{7,9} Hon et al. in their systematic review and prospective population-based study confirm that the presentation and clinical course of DVAs are usually benign.¹⁰

CA is a congenital blood-vessel hamartoma formed by endothelined sinusoidal vascular spaces.⁹ CAs are even less frequently found than DVAs, accounting for 5% to 13% of all vascular lesions.¹¹ Vernooij et al. in their study based on incidental findings on 2000 MRI scans identified 0.4% patients with CA.¹² The clinical presentation of these lesions is highly variable, ranging from incidental findings on neuroimaging to discovery at autopsy after a fatal haemorrhage.¹¹ The most common symptoms of CAs are seizures followed by focal neurological deficits, acute haemorrhage, and headaches.¹³

The coexistence of a DVA and a CA is the most common mixed vascular malformation.⁷ An association between DVA and CA was described by Roberson in 1974.¹⁴ Based on findings from MR imaging studies, Abdulrauf et al identified 24% patients with CA who had associated DVA.¹⁵ while, based on MR imaging and intraoperative findings, Wurm et al. identified 25.9% patients.¹⁶ In 2007, Revert Ventura et al. identified 30% patients with CA who had associated DVA.⁵ While Abe et al. insisted that VAs share a common origin and pathogenic mechanism with CAs,¹⁷ Guclu et al. asserted that DVAs and CAs are two distinct entities with dif

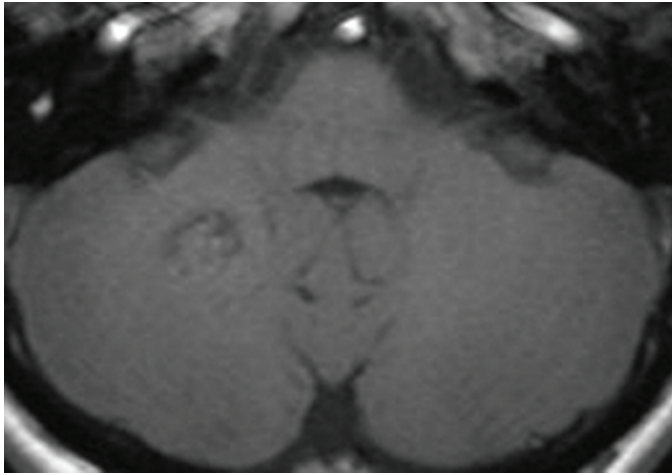


Figure 3. The axial unenhanced T1-weighted image shows the cavernous angioma in the right cerebellar hemisphere. There is no evidence of other abnormalities.

ferent pathogenetic mechanisms and that DVAs have a distinct biology and clinical behaviour when compared to CAs, using a gene study in a family whose members were affected by both disorders.¹⁸ In 2005, Wurm et al. reported that DVAs can be regarded as the primary lesion leading to the occurrence of mixed vascular malformations, and they suggest the continuum of progression of a single pathological process.¹⁹

The venous drainage in patients with CAs may be classic venous drainage or atypical venous drainage. Atypical venous drainage occurs when the venous structures have no connection to the transcortical venous system.²⁰ In our case venous drainage was classical.

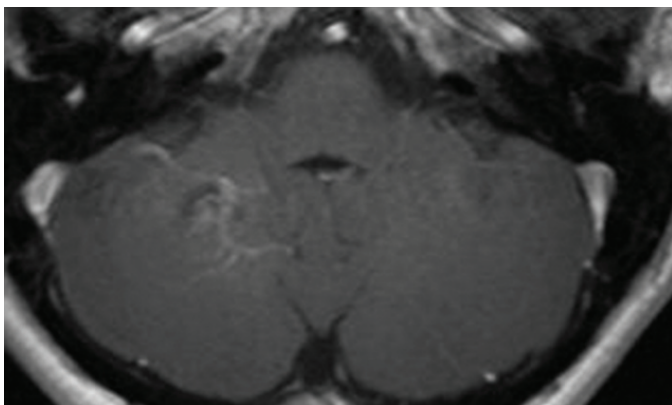


Figure 4. The axial contrast-enhanced T1-weighted image shows the venous angioma with its small dilated medullary veins distributed around and within the cavernous angioma that converge on a larger collector vein

The presence of a DVA in the close vicinity of a CA of the brain enhances the risk of bleeding from the CA. In the present case we only found microbleeds inside the

CA but no evidence of intracerebellar bleeding. VA and CA were found incidentally.

The relatively benign nature of CA obviates the need for any immediate resection unless they grow, become symptomatic or if bleedings occurs.¹³ In that case extirpation of CA with presentation of VA is recommended, but the associated DVA should be spared during surgery for CA. There is no indication for surgery on the VA because the risk of postoperative deterioration caused by venous infarction is high. If the main trunk is resected, venous engorgement and cerebral oedema can result, at times with devastating consequences.^{3,21} Therefore, it is very important to detect a VA in the close vicinity of a CA with radiological diagnostic modalities such as CT, MRI and angiograms. CT is good for detection of acute hematoma and calcification, while a T2-weighted gradient echo-pulse sequence is very sensitive to hemosiderin deposits surrounding a CA.

Although contrast-enhanced CT and non-enhanced MRI may reveal a VA, the preferred imaging technique is contrast-enhanced MRI because of its excellent depiction of the small venules and the draining vein which cannot be always detected on non-enhanced MRI scans, as in the present case. We only discovered the VA after contrast administration. Generally, cases of suspected CA should undergo an MRI scan with gradient echo imaging (to exclude or define multifocal lesions) and a gadolinium-enhanced study (to exclude or define associated VA).¹³

CONCLUSION

Isolated CA and VA are common vascular cerebral malformations, although their association is less frequent. This association is nevertheless important to acknowledge due to the bleeding risk and surgical planning. When extirpation of a CA is considered, the associated VA has to be preserved due to possible venous infarction. To detect a VA, the administration of contrast agents is necessary because small venules and the draining vein of VAs cannot always be detected on non-enhanced MRI scans. When in doubt, conventional angiography is warranted.

REFERENCES

1. McCormick WF. The pathology of vascular ("arteriovenous") malformations. *J Neurosurg.* 1996;24:807-16. doi:10.3171/jns.1966.24.4.0807 PMID:5934138
2. Awad IA, Robinson JR, Mohanty S, Estes ML. Mixed vascular malformations of the brain: clinical and pathogenetic considerations. *Neurosurgery.* 1993;33:179-88. doi:10.1227/00006123-199308000-00001 PMID:8367039

3. Perrini P, Lanzino G. The association of venous developmental anomalies and cavernous malformations: pathophysiological, diagnostic, and surgical considerations. *Neurosurg Focus*. 2006;21(1):e5. doi:10.3171/foc.2006.21.1.6
4. Ferrito G, Scazzeri F, Prosetti D, Nenci R, Quilici N, Marcacci G. Venous angioma associated with cavernous angioma: Presentation of three cases. *Riv Neurol*. 1990;60: 191–3. PMID:2100039
5. Revert Ventura AJ, Martí-Bonmatí L, Poyatos Ruipérez C, Pallardó Calatayud Y, Arana E, Mollá Olmos E. Association of cavernous and venous angiomas. *Neurología*. 2007;22(10):839-45. PMID:17671855
6. Martin NA, Wilson CB, Stein BM. Venous and cavernous malformations, in Wilson CB, Stein BM (eds): *Intracranial Arteriovenous Malformations*. Baltimore: Williams & Wilkins, 1984, pp 234-45.
7. Töpfer R, Jörgens E, Reul J, Thron A. Clinical significance of intracranial developmental venous anomalies. *J Neurol Neurosurg Psychiatry*. 1999;67:234-8. doi:10.1136/jnnp.67.2.234 PMID:50411
8. Wilms G, Bleus E, Demaerel P, Marchal G, Plets C, Goffin J, et al. Simultaneous occurrence of developmental venous anomalies and cavernous angiomas. *AJNR Am J Neuroradiol*. 1994;15:1247-57. PMID:7976933
9. Abla A, Wait SD, Uschold T, Lekovic GP, Spetzler RF. Developmental venous anomaly, cavernous malformation, and capillary telangiectasia: spectrum of a single disease. *Acta Neurochir (Wien)*. 2008;150:487–9. doi:10.1007/s00701-008-1570-5 PMID:18351283
10. Hon JM, Bhattacharya JJ, Counsell CE, Papanastassiou V, Ritchie V, Roberts RC, et al. The presentation and clinical course of intracranial developmental venous anomalies in adults: a systematic review and prospective, population-based study. *Stroke*. 2009;40(6):1980-5. doi:10.1161/STROKEAHA.108.533034 PMID:19390075
11. Maraire JN, Awad IA. Intracranial cavernous malformations: lesion behavior and management strategies. *Neurosurgery*. 1995;37:591-605. doi:10.1227/00006123-199510000-00001 PMID:8559286
12. Vernooij MW, Ikram MA, Tanghe HL, Vincent AJ, Hofman A, Krestin GP, et al. Incidental findings on brain MRI in the general population. *N Engl J Med*. 2007;357(18):1821-8. doi:10.1056/NEJMoa070972 PMID:17978290
13. Raychaudhuri R, Batjer HH, Issam AA. Intracranial cavernous angioma: a practical review of clinical and biological aspects. *Surgical Neurology*. 2005; 63:319–28. doi:10.1016/j.surneu.2004.05.032 PMID:15808709
14. Roberson GH, Kase CS, Wolpaw ER. Teleangiectases and cavernous angiomas of the brainstem: “cryptic” vascular malformations. Report of a case. *Neuroradiology*. 1974;8:83–9. doi:10.1007/BF00345039 PMID:4437757
15. Abdulrauf SI, Kaynar MY, Awad IA. A comparison of the clinical profile of cavernous malformations with and without associated venous malformations. *Neurosurgery*. 1999;44:41–7. doi:10.1097/00006123-199901000-00020 PMID:9894962
16. Wurm G, Schnizer M, Nussbaumer K, Wies W, Holl K. Recurrent cryptic vascular malformation associated with a developmental venous anomaly. *Br J Neurosurg*. 2003;17:188–95. PMID:12820766
17. Abe M, Asfora WT, DeSalles AA, Kjellberg RN. Cerebellar venous angioma associated with angiographically occult brain stem venous malformation: reports of two cases. *Surg Neurol*. 1990;33:400–3. doi:10.1016/0090-3019(90)90152-F
18. Guclu B, Ozturk AK, Pricola KL, Seker A, Ozek M, Gunel M. Cerebral venous malformations have distinct genetic origin from cerebral cavernous malformations. *Stroke*. 2005;36:2479–80. doi:10.1161/01.STR.0000183616.99139.d3 PMID:16239636
19. Wurm G, Schnizer M, Fellner FA. Cerebral cavernous malformations associated with venous anomalies: surgical considerations. *Neurosurgery*. 2008;57(1):42–58. doi:10.1227/01.NEU.0000163482.15158.5A PMID:15987569
20. Kamezawa T, Hamada JI, Niuro M, Kai Y, Ishimaru K, Kuratsu JI. Clinical implications of associated venous drainage in patients with cavernous malformation. *J Neurosurg*. 2005;102:24–8. doi:10.3171/jns.2005.102.1.0024 PMID:15658092
21. Porter RW, Detwiler PW, Spetzler RF, Lawton MT, Baskin JJ, Derksen PT, et al. Cavernous malformations of the brainstem: experience with 100 patients. *J Neurosurg*. 1999;90:50–8. doi:10.3171/jns.1999.90.1.0050 PMID:10413155